

WED-443

Quantification of vessel and bile duct parameters using Second Harmonic Generation in patients with NAFLD across fibrosis stages

Jörn Schattenberg¹, Yayun Ren², Dean Tai², Elaine Chng², Maurice Michel³, Christian Labenz³, Beate Straub⁴

¹Metabolic Liver Research Center, University Medical Center of the Johannes Gutenberg-University, Germany, ²HistoIndex Pte Ltd, Singapore, ³University Medical Center of the Johannes Gutenberg-University, Department of Medicine, Germany, ⁴University Medical Center of the Johannes Gutenberg-University, Department of Pathology, Germany

Email: joern.schattenberg@unimedizin-mainz.de

Background and Aims: Liver histology defines the pathophysiological alterations occurring in patients with NAFLD while they develop progressive (especially perisinusoidal) fibrosis and progress to liver cirrhosis. Fibrosis and cirrhosis are defined by changes in the vascularisation as well as bile ducts, but they have not been systematically assessed in patients with NAFLD so far. The aim of this exploratory analysis was done to identify features of the hepatic vasculature and bile ducts using second harmonic generation imaging (SHG) and to correlate them with the histological fibrosis scores.

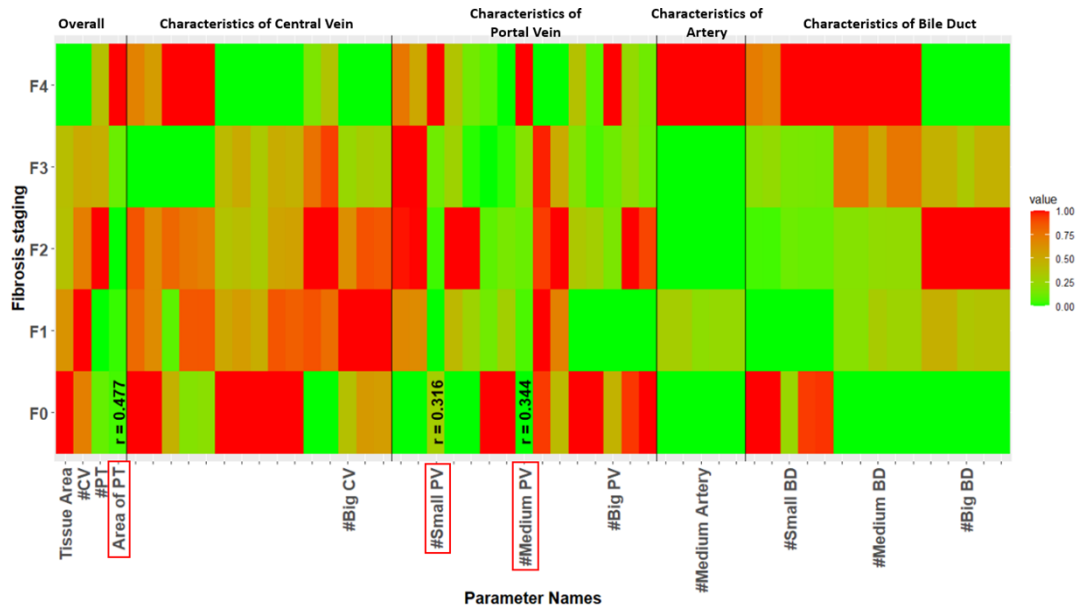
Method: Unstained sections from 132 patient with NAFLD that underwent liver biopsy between 2016 and 2018 for suspected NASH were included. Fibrosis staging was done based on the NASH CRN fibrosis score on Gomöri and evG stained liver biopsies. Second harmonic generation/two-photon excitation fluorescence (SHG/TPEF) microscopy was done using unstained liver sections.

Results: Among the 132 patients, 52.7% were male with a mean age of 54 years [43.0-60.0] and a mean BMI of 32.2 kg/m² [28.7-37.0]. Laboratory findings included ALT (U/l) 73.0 [50.0-115.7], AST 50 [38-67], gGT 109 [60.7-115.7], A1c 6.0 [5.4-6.9]. Mean transient elastography was 8.2 kPa [5.7 – 13.2]. Comorbidities included Type 2 Diabetes (41.2%), arterial hypertension (72.5%), hypertriglyceridemia (32.8%) and obesity (BMI >30; 54.2%). Advanced fibrosis was present in 34.4% of liver biopsies. The histological fibrosis stages were distributed, according to Kleiner, as follows F0 (3.1 %), F1a-c (27.5%), F2 (35.1%), F3 (23.7%) and F4 (10.7%).

SHG was used to quantify histological characteristics of the intrahepatic vasculature. A total of 50 pathological changes, including those of central veins, portal veins, arteries, as well as bile ducts and their respective morphological features were identified and quantified. The correlation of these features with fibrosis stages are shown as a heat map in the figure attached. A pattern that followed fibrosis stages was seen in portal tracts. The total area of portal tracts (Rho=0.477), as well as the small (Rho=0.316) and medium-sized portal vein (Rho=0.344) branches increased progressively across fibrosis stages. In addition, features of arteries were relatively stable between disease stages from F0 to F3 but a sudden drop in correlations with arteries was observed at F4.

Conclusion: In patients with histologically defined NAFLD, alterations of the central veins, portal veins, as well as of bile ducts in the liver are correlated with increasing fibrosis stages with the exception of arteries. With onset of cirrhosis, changes are dramatically altered. Additional work is in progress to correlate this vasculature information to clinical data and other non-invasive tests results.

Figure: Heatmap indicated the correlation of histological characteristics with fibrosis stages. The range of characteristics was normalized to 0-1. Three features with largest coefficients were highlighted, including the total area of portal tract (Area of PT), number of small portal vein (#Small PV) and number of medium portal vein (#Medium PV). The correlation coefficient was calculated by Spearman's correlation method.



Jörn M. Schattenberg¹, Yayun Ren², Dean Tai², Elaine L. K. Chng², Maurice Michel³, Christian Labenz³, Beate K. Straub⁴

¹Metabolic Liver Research Center, I. Department of Medicine, University Medical Center of the Johannes Gutenberg-University, Mainz, Germany

²Histoindex Pte. Ltd., Singapore

³I. Department of Medicine, University Medical Center of the Johannes Gutenberg-University, Mainz, Germany

⁴I. Department of Pathology, University Medical Center of the Johannes Gutenberg-University, Mainz, Germany

INTRODUCTION

- Liver histology defines the pathophysiological alterations occurring in patients with NAFLD while they develop progressive (especially perisinusoidal) fibrosis and progress to liver cirrhosis.
- Fibrosis and cirrhosis are defined by changes in the vascularisation as well as bile ducts, but they have not been systematically assessed in patients with NAFLD so far.

AIM

- The aim of this exploratory analysis was done to identify features of the hepatic vasculature and bile ducts using second harmonic generation imaging (SHG) and to correlate them with the histological fibrosis scores.

METHOD

- Unstained sections from 132 patient with NAFLD that underwent liver biopsy between 2016 and 2018 for suspected NASH were included.
- Fibrosis staging was done based on the NASH CRN fibrosis score on Gomöri and evG stained liver biopsies.
- Second harmonic generation/two-photon excitation fluorescence (SHG/TPEF) microscopy was done using unstained liver sections.¹

RESULTS

- Among the 132 patients, 52.7% were male with a mean age of 54 years [43.0-60.0] and a mean BMI of 32.2 kg/m² [28.7-37.0].
- Laboratory findings included ALT (U/l) 73.0 [50.0-115.7], AST 50 [38-67], gGT 109 [60.7-115.7], A1c 6.0 [5.4-6.9]. Mean transient elastography was 8.2 kPa [5.7 – 13.2]. Comorbidities included Type 2 Diabetes (41.2%), arterial hypertension (72.5%), hypertriglyceridemia (32.8%) and obesity (BMI >30; 54.2%).
- Advanced fibrosis was present in 34.4% of liver biopsies.
- The histological fibrosis stages were distributed, according to Kleiner, as follows F0 (3.1 %), F1a-c (27.5%), F2 (35.1%), F3 (23.7%) and F4 (10.7%).
- SHG was used to quantify histological characteristics of the intrahepatic vasculature.
- A total of 50 pathological changes, including those of central veins, portal veins, arteries, as well as bile ducts and their respective morphological features were identified and quantified.

CONCLUSIONS

- In patients with histologically defined NAFLD, alterations of the central veins, portal veins, as well as of bile ducts in the liver are correlated with increasing fibrosis stages with the exception of arteries. With onset of cirrhosis, changes are dramatically altered.
- Additional work is in progress to correlate this vasculature information to clinical data and other non-invasive tests results.

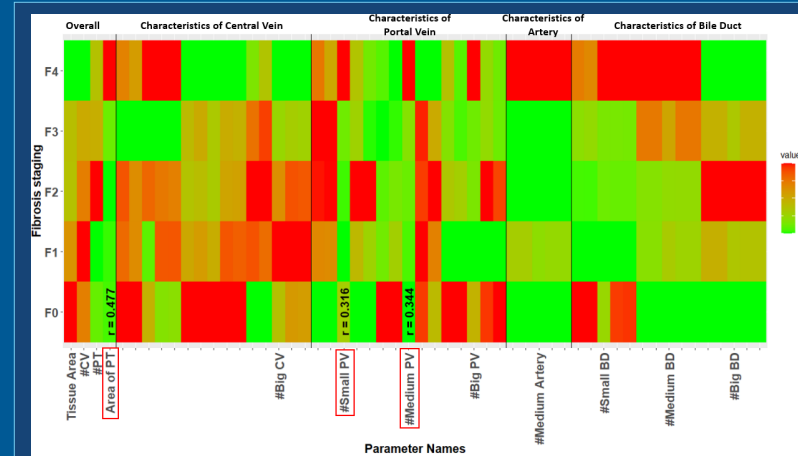


Figure 1: Heatmap indicated the correlation of histological characteristics with fibrosis stages. The range of characteristics was normalized to 0-1. Three features with largest coefficients were highlighted, including the total area of portal tract (Area of PT), number of small portal vein (#Small PV) and number of medium portal vein (#Medium PV). The correlation coefficient was calculated by Spearman's correlation method.

- Figure 1: The correlation of these features with fibrosis stages are shown as a heatmap, where a pattern that followed fibrosis stages was observed in portal tracts.
- The total area of portal tracts (Rho=0.477), as well as the small (Rho=0.316) and medium-sized portal vein (Rho=0.344) branches increased progressively across fibrosis stages.
- In addition, features of arteries were relatively stable between disease stages from F0 to F3, but a sudden drop in correlations with arteries was observed at F4.

REFERENCES

1. Liu F, Goh GBB, Tiniakos D, Wee A, Leow WQ, Zhao JM, et al. qFIBS: an automated technique for quantitative evaluation of fibrosis, inflammation, ballooning, and steatosis in patients with nonalcoholic steatohepatitis. *Hepatology* 2020;71:1953–1966

ACKNOWLEDGEMENTS

All authors participated in the development of this poster and approved the final poster for presentation.

CONTACT INFORMATION

Joern.Schattenberg@unimedizin-mainz.de